

ARTICLE LINKS:[Abstract](#) | [References \(27\)](#) | [View full-size inline images](#)

Plastic & Reconstructive Surgery: Volume 104(5) October 1999 pp 1524-1531

Combined Gluteoplasty: Liposuction and Lipoinjection**[Cosmetic]**Cárdenas-Camarena, Lázaro M.D.; Lacouture, Alberto Mario M.D.; Tobar-Losada, Angel M.D.
Jalisco, MexicoPlastic Surgery Unit; Av. Chapalita 1300 Col. Chapalita; Guadalajara, Jalisco 45000; México;
plassurg@foreigner.class.udg.mx (Cárdenas-Camarena)

From the Reconstructive Surgery Institute of Jalisco.

Received for publication January 4, 1999; revised March 31, 1999.

Abstract [TOP](#)

From April of 1995 to August of 1998, 62 female and four male patients had gluteoplasties. To improve the gluteal region, two techniques that create excellent results in other parts of the body, liposuction and lipoinjection, were combined. The ages of the patients ranged from 18 to 52 years (mean, 31 years). Liposuction was done with a tumescent technique in the lumbosacral, trochanteric, and subgluteal region to improve gluteal shape. The amount of fat aspirated was only that necessary to obtain the desired contour. In all cases, liposuction was also performed in other areas. Lipoinjection was done with round-tip cannulas in different planes of the gluteal region, and the fat was applied in small strips. The quantity of fat infiltrated varied from 120 to 280 cc per gluteus, with a mean of 210 cc. The results were evaluated by the patients and the surgical team with preoperative and post-operative photographs. Follow-up ranged from 3 months to 3 years and 5 months, with a mean of 17 months. No patient was dissatisfied with the results, and more than 90 percent considered their results good or excellent. Liposuction complications consisted of four seromas, six visible irregularities, and two palpable irregularities. Lipoinjection complications occurred in 16 gluteus regions (12 percent); all had gluteal temporal hyperemia and erythema, which resolved with conservative treatment except in one case (4 cc of sterile material corresponding to fat necrosis was drained in that patient). No irregularities or depressions occurred in the gluteus. One case of probable fat embolism syndrome had a satisfactory evolution. This gluteoplasty technique is simple and low in cost, with minimal morbidity and very good results. It is important to note that a good result does not depend on a great amount of fat infiltration but rather on a harmonious way of combining both surgical procedures: fat elimination by liposuction and gluteus augmentation by lipoinjection.

An improvement in body contour is frequently requested by aesthetic surgery patients. At the present time, correcting the gluteal contour is one of the main objectives for patients who wish to obtain an adequate body shape. Gluteal contouring surgery includes a great variety of procedures that are performed in multiple ways. Pitanguy¹ and Regnault et al.² improve the gluteal shape by resecting tissue in the trochanteric region and gluteal fold. Gonzalez-Ulloa³ and Lockwood⁴ obtain a better shape by elevating the entire gluteal region. With the development of implants, various authors have obtained good results with augmentation gluteoplasty.^{5,6} After the introduction of liposuction,^{7,8} a new alternative was available for the treatment of body contouring and improvement of the gluteal region.⁹⁻¹¹ The evidence of fat survival in long-term follow-up studies constitutes another option for obtaining better aesthetic results in multiple areas of the body,¹²⁻¹⁹ including the buttocks.²⁰ On the basis of the experiences of the authors cited here, we decided to perform liposuction in the adjacent gluteal regions and combine it with lipoinjection of the area to improve contour.

Patients and Methods [TOP](#)

During a 3-year and 5-month period, from April of 1995 to August of 1998, 66 patients were operated on. There were 62 women and four men, who ranged in age from 18 to 52 years (mean, 31 years), in the series. All had liposuction performed in different areas of the body to improve contour. The gluteal areas that had liposuction included the lumbosacral region, the trochanteric region, and the inferior part of the subgluteal fold. In the same way, fat injection was done in the gluteal region in different quantities. Preoperative analyses were performed in all the patients; these included determinations of hemoglobin, hematocrit, prothrombin time, partial thromboplastin time, and serum glucose, urea, and creatinine, and urinalysis. In those patients older than 45 years or with significant medical histories, a complete medical evaluation was performed before surgery by a doctor of internal medicine; the evaluation included a resting electrocardiogram. In many patients, additional aesthetic procedures besides gluteal improvement were performed. In all patients, the results were evaluated with preoperative and postoperative photographs ([Figs. 1 through 3](#)). Evaluations considered the patients' satisfaction and the

Article Outline[Abstract](#)[Patients and Methods](#)

- [Surgical Technique](#)

[Results](#)[Discussion](#)[Acknowledgments](#)[REFERENCES](#)**Figures/Tables**[Fig. 1](#)[Fig. 2](#)[Fig. 3](#)[Fig. 4](#)[TABLE I Additional S...](#)[TABLE II Areas Lipos...](#)[TABLE III Volume of ...](#)[TABLE IV Complicatio...](#)[TABLE V Rating of th...](#)

assessment of the surgical team; a scale of 1 to 4 was used to rate the degree of patient and surgical team satisfaction (1, a bad result; 4, excellent improvement).

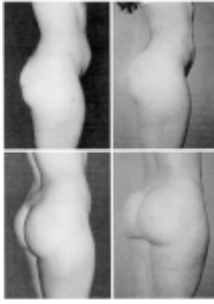


Fig. 1. A 26-year-old woman shown 8 months after surgery (*right*). She had an adequate preoperative gluteal size (*left*), but she acquired a better shape after the lipoinjection of 210 cc in each gluteus. The patient had a preoperative gluteal depression that was not treated.

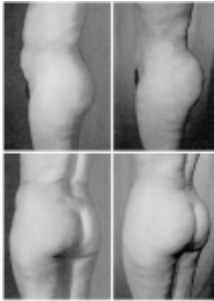

Fig. 2. A 42-year-old woman shown 14 months after surgery (*right*). The patient presented preoperatively with inadequate superior gluteal shape because of fat excess in the lumbosacral region (*left*). Improvement of the superior gluteal contour occurred with the lipoinjection of 120 cc and lumbosacral liposuction. The inferior contour improved after subgluteal liposuction. An abdominoplasty was performed at the same time.

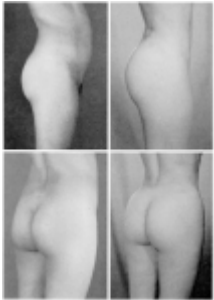

Fig. 3. A 25-year-old woman shown before (*left*) and 2 years after surgery (*right*). She had liposuction in the lumbosacral region and lipoinjection of 230 cc. This patient had a long-term follow-up, which shows that the results of the gluteal region improvement were maintained.

Surgical Technique [TOP](#)

Liposuction was performed using the tumescent technique in all patients. Antibiotic prophylaxis was done with 1 g of cephalexin, given 6 hours before surgery and continued once every 8 hours for 24 hours after surgery. In the immediate preoperative period, a single hydrocortisone dose was given. The majority of patients were managed with lidocaine peridural blockade; only those with multiple procedures or with contraindications for regional blockade received general inhalation anesthesia. The areas to be liposuctioned or lipoinjected were marked preoperatively with the patient standing up. Lumbosacral liposuction was done in all cases, whereas subgluteal and trochanteric liposuction were done only when indicated. The lipoinjection zone included the upper middle gluteus. Liposuction was performed using the tumescent technique; a solution consisting of 1 liter of 0.9% saline and 1 mg of adrenaline was used for infiltration. With the patient in the ventral decubitus position, liposuction of the lumbosacral region is done using incisions in the upper part of the intergluteal fold and the upper part of the iliac crest. Incisions in the subgluteal fold are also made when this area or the trochanteric region is treated. Liposuction is performed with a Cosmetech liposuction machine (model SSB-IV) and 3-mm cannulas, using sterilized containers to collect the aspirated material. This material is decanted for 30 minutes to separate the infranatant liquid and the supernatant fat. The fat to be lipoinjected is obtained from the initial aspirated material, so it is cleaner. Using 60-cc syringes and round-tip cannulas with three holes, lipoinjection of the preoperative marked area is performed. This is done through the liposuction incisions, and the muscular and subcutaneous planes are infiltrated. Liposuctioned and lipoinjected areas are shown in [Figure 4](#). Infiltration is done by moving the syringe continuously to avoid placing large fat volumes in a single place and to prevent fat necrosis. A specific postoperative position of the patient is not necessary. All patients wore an elastic garment for 6 weeks postoperatively. Beginning with the second postoperative week, therapeutic massages are given for 15 days in the treated areas.

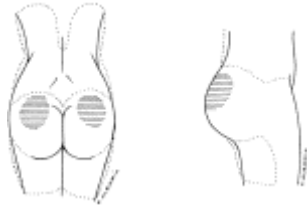


Fig. 4. Liposuctioned and lipoinjected areas. The dotted lines represent the liposuctioned areas, and the horizontal solid lines represent the lipoinjected areas.

Results ^{TOP}

The follow-up period ranged from 3 months to 3 years and 5 months, with a mean of 17 months. In all patients, liposuction was also done in areas other than those treated for gluteal improvement. In the same way, additional aesthetic procedures were performed in 18 patients (27 percent); in five of them more than one additional procedure was done. These procedures included abdominoplasty in eight patients, mammary implants in six, reduction mammoplasty in four, mastopexy with implants in four, and minirhinoplasty in one ([Table I](#)).

Procedure	No. of Patients	Percentage
General liposuction	66	100
Abdominoplasty	8	12
Mammary implants	6	9
Reduction mammoplasty	4	6
Mastopexy and implants	4	6
Minirhinoplasty	1	1.5

TABLE I Additional Surgical Procedures

To improve gluteal shape, liposuction of the lumbosacral region was done in all patients; in 59 patients (89 percent), it was done below the subgluteal fold, and in 48 patients (73 percent), it was done in the trochanteric region ([Table II](#)). In male patients, only lumbosacral liposuction was required. The volumes of infiltrated fat varied from 120 to 280 cc per gluteus, with a mean of 210 cc. In all patients, the same amount of fat was injected in each gluteus. The amounts of fat infiltrated per group of patients are indicated in [Table III](#).

Region	No. of Patients	Percentage
Lumbosacral	66	100
Subgluteal	59	89
Trochanteric	48	73

TABLE II Areas Liposuctioned to Improve Gluteal Shape

Volume (cc)	No. of Patients	Percentage
120-180	9	13.6
181-210	29	43.9
211-240	34	51.5
241-280	6	9.1

TABLE III Volume of Fat Infiltrated in Each Gluteus

Complications from the procedure are as follows. Four patients (6 percent) presented with seromas in the lumbosacral area; they were drained without sequelae. Six patients (9 percent) had palpable irregularities in the liposuctioned area; they were visible in only two patients (3 percent). Sixteen gluteus regions (12 percent) in 12 patients had erythema and hyperemia of the infiltrated zone, which began a mean of 5 days postoperatively and disappeared after a mean of 9 days postoperatively. All patients with this complication except one were handled successfully with conservative treatment, which consisted of hot drapes, anti-inflammatory drugs, and antibiotics. In one patient, 4 cc of liquid corresponding to fat necrosis was drained; no posterior irregularities occurred. In all cases, more than 230 cc of fat was infiltrated per gluteus. No patient had irregularities or induration of the infiltrated area. One patient in whom two additional procedures were done (abdominoplasty and mammary implants) presented with probable fat embolism syndrome. Symptoms began on the third postoperative day, but they resolved satisfactorily. In this patient, 3600 cc was removed by liposuction and 210 cc of fat was infiltrated in each gluteus. Complications are summarized in [Table IV](#).

Complication	No. of Patients	Percentage
Lumbosacral seroma	4	6
Visible irregularities	6	9
Palpable irregularities	2	3
Transient gluteal erythema/hyperemia	16*	24*
Probable fat necrosis	1	1.5
Probable fat embolism syndrome	1	1.5

* 12 patients (18 percent) had 16 gluteus regions (12 percent) with affected.

TABLE IV Complications

All patients had improvement of the gluteal contour with the combination of the two techniques; none were dissatisfied with the results. The satisfaction ratings of the patients and the surgical team are presented in [Table V](#).

Results	Patients' Evaluation		Surgical Evaluation	
	No.	%	No.	%
1 (Bad)	0	0	0	0
2 (Moderate)	3	4.5	3	4.5
3 (Good)	32	48.5	30	45.5
4 (Excellent)	31	46.9	32	48.5

TABLE V Rating of the Results

Discussion [TOP](#)

Improving the gluteal contour has been a major concern for many authors for some time.[1,5,6,20](#) At the present time, patients have various, different alternatives because of the arrival of new techniques. Some procedures achieve improvement but create large, visible scars.[1,4](#) Undoubtedly, one advance is the use of gluteal implants, because gluteal augmentation provides adequate support and contour of the region with minimal scars.[5,6](#) However, the implants have the disadvantages of cost and the aversion that many patients have for the use of foreign material in their bodies.

A lack of definition in gluteal contour occurs in many Latin patients because of an inadequate distribution of fat in the region; basically, there is fat excess in the peripheral gluteal zones and a lack of adipose tissue in the superior gluteal portion. This contributes to the loss of gluteal contouring, although fat quantity is sufficient in the area. The physical characteristics of the gluteal contour in Latin women differ from those of Caucasian women. In Latin women, it is common to find gluteal projection with a small waist. This type of gluteal contour is more similar to the physiognomy of Negroid women than it is to the Anglo-Saxon contour. Because of these ethnic characteristics, in Latin culture, it is common for patients to request a prominent gluteal contour with a thin waist.

The described technique was, thus, used to improve gluteal contour; in many cases, projection of the gluteus was achieved. Considering the desires of our patients and using the principle of removing fat from where it is in excess and putting it where it is needed, we decided to improve gluteal contour by combining two surgical procedures that have given excellent results in plastic surgery: liposuction and lipoinjection. Liposuction is the best choice for body contouring.[9-11](#) In the same way, multiple studies have demonstrated the benefits that can be obtained with fat infiltration for diverse purposes in different body areas.[12-18](#) Many authors emphasize the use of good technique to obtain better survival of the injected fat.[12-18](#) Experience with lipoinjection in the gluteal region, with satisfactory results, also exists.[20](#)

We obtained favorable results in patients by using a combination of these two techniques. More than 90 percent of our patients showed improvement, as determined by the evaluation done postoperatively by surgeons and patients. It is important to emphasize that fat excess in the lumbosacral region is one of the basic factors that must be corrected to obtain adequate gluteal shape. For this reason, it was necessary to perform liposuction in this area in all patients. Contouring the subgluteal and trochanteric regions was required in a large number of patients but not in all of them. The majority of patients had improvement with a lipoinjection of less than 240 cc in each gluteus; there was no relationship between the volume infiltrated and the degree of patient and surgical team satisfaction. The complications that occurred were those common for these types of procedures in type and frequency. Erythema, hyperemia, and fat necrosis in the lipoinjected areas, which occurred in a low proportion of patients, were exclusively related to those cases in which infiltration was more than 230 cc per gluteus. For this reason, the amount of fat infiltrated is one of the variables to consider to prevent local reaction and fat necrosis. The probable fat embolism syndrome presented in one of our cases is an entity that deserves special attention because its appearance is not explained exclusively by lipoinjection; it has been reported after small-volume liposuction performed as a single surgical procedure.[21-23](#) The correlation of multiple factors in the occurrence of this syndrome requires a deeper study and evaluation to find its cause during liposuction.

There are important aspects of the surgical technique that are essential to obtain good results. Doing liposuction with the tumescent technique allows the surgeon to suction the amount of fat necessary to obtain a good body contour without having the volume aspirated as a limiting factor.[24-27](#) In the same way, the tumescent technique has permitted us to suction very clean fat tissue. We have not needed additional procedures to clean this fat tissue, as other authors have.[13,15](#) Letting the fat decant for a certain time allows us to obtain clean fat for infiltration. Using the same small-diameter cannulas to suction and infiltrate fat tissue provides an easier application of the fat. Infiltration is always done in the upper middle part of the gluteus in an oval or circular form, depending on each patient. Infiltration in the upper portion favors buttock elevation. Fat infiltration in different planes and in multiple directions guarantees symmetrical results. Also, using a continuous movement of the syringe during fat infiltration and different planes avoids fat necrosis and having large quantities of fat accumulate in one area. By applying these principles, our complications have diminished and the results have improved considerably with time.

The improvement that can be obtained with the combined technique of liposuction and lipoinjection depends on the quantity of fat that can be removed in adjacent gluteal areas and on the amount of volume that is needed in the gluteal region. When more fat is suctioned, the result is more evident. It is for this reason that better results are obtained when the needed augmentation is less than 260 cc. Although we cannot objectively and precisely measure the survival of the injected fat, this technique is a simple, low cost procedure with minimal morbidity and very good results. The gluteal shape obtained after prolonged follow-up is satisfactory and demonstrates considerable fat survival over a long period of time. A good result does not depend on a large gluteus augmentation; it depends on combining the two procedures in a harmonious way to give the patient an ideal body contour, eliminating fat deposits with liposuction and applying fat where it is necessary by lipoinjection.

Lázaro Cárdenas-Camarena, M.D.

Plastic Surgery Unit; Av. Chapalita 1300 Col. Chapalita; Guadalajara, Jalisco 45000; México;

plassurg@foreigner.class.udg.mx

Acknowledgments [TOP](#)

The authors thank Francisco Ruvalcaba, M.D., Francisco Alegria, M.D., and Víctor Hugo Gómez Peña for their help in preparing the photographic material of the work.

REFERENCES [TOP](#)

1. Pitanguy, I. Trochanteric lipodystrophy. *Plast. Reconstr. Surg.* 34: 280, 1964.
[\[Medline Link\]](#) [\[CrossRef\]](#) [\[Context Link\]](#)
2. Regnault, P., Baroudi, R., and da Silveira Carvalho, C. G. Correction of lower limb lipodystrophy. *Aesthetic Plast. Surg.* 3: 233, 1979.
[\[Context Link\]](#)
3. Gonzalez-Ulloa, M. Gluteoplasty: A 10-year report. *Aesthetic Plast. Surg.* 15: 85, 1991.
[\[Medline Link\]](#) [\[Context Link\]](#)
4. Lockwood, T. E. Transverse flank-thigh-buttock lift with superficial fascial suspension. *Plast. Reconstr. Surg.* 87: 1019, 1991.

- [\[Medline Link\]](#) [\[CrossRef\]](#) [\[Context Link\]](#)
5. Novack, B. H. Alloplastic implants for men. *Clin. Plast. Surg.* 18: 829, 1991.
- [\[Medline Link\]](#) [\[Context Link\]](#)
6. Vergara, R., and Marcos, M. Intramuscular gluteal implants. *Aesthetic Plast. Surg.* 20: 259, 1996.
[\[CrossRef\]](#) [\[Context Link\]](#)
7. Schrudde, J. Lipexeresis as a means of eliminating local adiposity. *Aesthetic Plast. Surg.* 4: 215, 1980.
[\[Context Link\]](#)
8. Kesselring, U. K. Regional fat aspiration for body contouring. *Plast. Reconstr. Surg.* 72: 610, 1983.
[\[Medline Link\]](#) [\[CrossRef\]](#) [\[Context Link\]](#)
9. Illouz, Y. G. Body contouring by lipolysis: A 5-year experience with over 3000 cases. *Plast. Reconstr. Surg.* 72: 591, 1983.
[\[Medline Link\]](#) [\[CrossRef\]](#) [\[Context Link\]](#)
10. Baroudi, R. Body sculpturing. *Clin. Plast. Surg.* 11: 419, 1984.
[\[Medline Link\]](#) [\[Context Link\]](#)
11. Gasparotti, M. Superficial liposuction: A new application of the technique for aged and flaccid skin. *Aesthetic Plast. Surg.* 16: 141, 1992.
[\[Medline Link\]](#) [\[CrossRef\]](#) [\[Context Link\]](#)
12. Guerrerosantos, J., Gonzalez-Mendoza, A., Masmela, Y., Gonzalez, M. A., Deos, M., and Diaz, P. Long term survival of free fat grafts in muscle: An experimental study in rats. *Aesthetic Plast. Surg.* 20: 403, 1996.
[\[CrossRef\]](#) [\[Context Link\]](#)
13. Coleman, S. R. Facial recontouring with lipostructure. *Clin. Plast. Surg.* 24: 347, 1997.
[\[Context Link\]](#)
14. Chajchir, A. Fat injection: Long-term follow-up. *Aesthetic Plast. Surg.* 20: 291, 1996.
[\[CrossRef\]](#) [\[Context Link\]](#)
15. Coleman, S. R. Long-term survival of fat transplants: Controlled demonstrations. *Aesthetic Plast. Surg.* 19: 421, 1995.
[\[CrossRef\]](#) [\[Context Link\]](#)
16. Niechajev, I., and Sevcuk, O. Long-term results of fat transplantation: Clinical and histologic studies. *Plast. Reconstr. Surg.* 94: 496, 1994.
[\[CrossRef\]](#) [\[Context Link\]](#)
17. Chajchir, A., and Benzaquen, I. Fat-grafting injection for soft-tissue augmentation. *Plast. Reconstr. Surg.* 84: 921, 1989.
[\[Medline Link\]](#) [\[CrossRef\]](#) [\[Context Link\]](#)
18. Billings, E., Jr., and May, J. W., Jr. Historical review and present status of free fat graft autotransplantation in plastic and reconstructive surgery. *Plast. Reconstr. Surg.* 83: 368, 1989.
[\[Medline Link\]](#) [\[CrossRef\]](#) [\[Context Link\]](#)
19. Toledo, L. S. Syringe liposculpture: A 2-year experience. *Aesthetic Plast. Surg.* 15: 321, 1991.
[\[Medline Link\]](#) [\[Context Link\]](#)
20. Pereira, L. H., and Radwanski, H. N. Fat grafting of the buttocks and lower limbs. *Aesthetic Plast. Surg.* 20: 409, 1996.
[\[CrossRef\]](#) [\[Context Link\]](#)
21. Ross, R. M., and Johnson, G. C. Fat embolism after liposuction. *Chest* 93: 1294, 1988.
[\[Context Link\]](#)
22. Laub, D. R., Jr., and Laub, D. R. Fat embolism syndrome after liposuction: A case report and review of the literature. *Ann. Plast. Surg.* 25: 48, 1990.
[\[Medline Link\]](#) [\[CrossRef\]](#) [\[Context Link\]](#)
23. Boezaart, A. P., Clinton, C. W., Braun, S., Oettle, C., and Lee, N. P. Fulminant adult respiratory distress syndrome after suction lipectomy: A case report. *S. Afr. Med. J.* 78: 693, 1990.
[\[Medline Link\]](#) [\[Context Link\]](#)
24. Cárdenas-Camarena, L., Tobar-Losada, A., and Lacouture, M. A. Large volume circumferential liposuction with tumescent technique: Sure and viable procedure. Submitted for publication.
[\[Context Link\]](#)
25. Klein, J. A. Tumescent technique for local anesthesia improves safety in large-volume liposuction. *Plast. Reconstr. Surg.* 92: 1085, 1993.
[\[CrossRef\]](#) [\[Context Link\]](#)
26. Samdal, F., Amland, P. F., and Bugge, J. F. Blood loss during suction-assisted lipectomy with large volumes of dilute adrenaline. *Scand. J. Plast. Reconstr. Surg. Hand Surg.* 29: 161, 1995.
[\[Context Link\]](#)
27. Cárdenas-Camarena, L., and Gonzalez, L. E. Large-volume liposuction and extensive abdominoplasty: A feasible alternative for improving body shape. *Plast. Reconstr. Surg.* 102: 1698, 1998.
[\[Fulltext Link\]](#) [\[CrossRef\]](#) [\[Context Link\]](#)